



ACUTE CLOSED ANGLE GLAUCOMA : A CASE REPORT

Helen Cyntia Mago

Rumah Sakit Umum Daerah Ibnu Sina Gresik, East Java, Indonesia

helenmago515@gmail.com

Received: 26-10-2023

Accepted: 01-11-2023

Published: 01-12-2023

ABSTRACT

Glaucoma is an eye disorder characterized by disruption of the tissue and integrity of eye function. This study aims to describe a case of Glaucoma along with an explanation and management of its therapy so that it can help increase knowledge and detect it early. This type of research is a descriptive case study. The research was conducted at an eye clinic on February 12 2022 on patients who were diagnosed with acute angle closure glaucoma through anamnesis and direct physical examination of the patient. Based on the results of the anamnesis and physical examination obtained, Mrs. K was diagnosed with acute left angle closure glaucoma, an eye disorder that occurs due to a rapid increase in intraocular pressure as a sign of anterior eye closure. room, blocking the flow of aqueous humor. In this case, Timolol maleate 0.5% ED 2 dd gtt 1 OS therapy was given, a beta (β)-adrenergic receptor antagonist whose function is to reduce aqueous humor production. Apart from that, Acetazolamide 250 mg 3x1 therapy was also given, which is a class of carbonic anhydrase inhibitor which functions to suppress the production of aqueous humor. The conclusion of this study is that the most common cause of glaucoma is obstruction of aqueous humor outflow due to pupillary blockade, closure of the angle of the anterior chamber, narrowing of the trabecular meshwork and increased episcleral venous pressure thereby increasing intraocular pressure.

Keywords: Glaucoma, Glaucoma Primary Closed Angel, obstruction of aqueous humor flow, increased intraocular.

Correspondent: Helen Cyntia Mago

Email: helenmago515@gmail.com



INTRODUCTION

Glaucoma is an eye disease that can cause sudden loss of vision, so it is known as "Sight Thief" because there are no apparent symptoms at the start of the disease. Damage or loss of vision caused by Glaucoma is permanent, so if early examination and appropriate treatment are not carried out, it can cause permanent blindness (Ayi Marini, 2018).

Glaucoma has become a common eye health problem in society. Based on data from the World Health Organization (WHO), in 2019, it is estimated that 6.9 million people throughout the world will experience visual impairment due to Glaucoma. It is estimated that in 2020, this will increase to 76 million people throughout the world who will experience visual impairment due to Glaucoma. The incidence of visual impairment due to Glaucoma is predicted to continue to increase until it reaches 111.8 million people in 2040. In Asia, the prevalence of Glaucoma is estimated at 47% of total cases. In Indonesia, it is estimated that there are 80,548 new cases of Glaucoma with characteristics occurring in those aged > 44 years and predominantly by women, namely 43,413 sufferers, while men accounted for 37,135 sufferers (Ice Rerung et al., 2021).

The leading cause of Glaucoma is increased intraocular pressure, so glaucoma treatment focuses on reducing intraocular pressure (Brown et al., 2014). In several Randomized Controlled Trial (RCT) studies, it has been found that reducing intraocular pressure can reduce the progression of Glaucoma and prevent the incidence of Glaucoma in sufferers of ocular hypertension. Treatment for

lowering intraocular pressure needs to be balanced by paying attention to factors that can trigger the progression of Glaucoma, namely old age, intraocular pressure that is too high, disc hemorrhage, other complications or damage, and pseudoexfoliation glaucoma (EGS, 2017).

This research aims to describe a case of Glaucoma along with an explanation and management of therapy so that it can help increase knowledge that it can detect glaucoma cases early and provide further therapy.

METHOD

This type of research is a descriptive case study. This research method describes the problems that occur by describing the problems that occur. This research was carried out at the eye clinic on February 12, 2022, on a patient diagnosed with acute angle closure glaucoma through anamnesis and direct physical examination of the patient after the patient stated that he was willing to be examined through verbal informed consent.

RESULTS AND DISCUSSION

Patient Mrs. K, 32, year-old, came to the eye clinic with complaints of severe pain in his left eye since approximately 1 day ago. Pain radiates to the head and is accompanied by nausea and vomiting. Complaints accompanied by a sudden decrease in vision in the left eye. The patient said the left eye felt blurry. The patient also reported complaints of red, watery eyes and complaints of seeing rainbow colors around the light source in the left eye. Apart from that, the patient experienced difficulty in walking due to blurred vision in the left eye and severe pain from the left eye area to the head, which interfered with the patient's activities (Ridiansyah et al., 2022).

The patient said this was the first complaint because the patient had never experienced a complaint like this before. The patient denied any history of diabetes mellitus, hypertension, asthma, drug or food allergies and history of trauma. The patient also said that he had never had a history of any eye disease before (Fitriana & Sureskiarti, 2018).

The patient said that there were family members who had experienced similar complaints. The patient's family has a history of asthma, diabetes mellitus and hypertension (Juliawan & Mayasari, 2023). The patient is a housewife with 2 small children (Winangsih & Sariyani, 2021). Patients routinely maintain cleanliness on their faces, and in the residential area, no one has ever suffered from eye disorders similar to the patient's or other eye diseases (Fatmawaty, 2019). The patient said that since the first complaint, the patient had never sought treatment or taken any medication before (Bustami et al., 2022).

On physical examination, it was found that his general condition was fair, composed of mentis consciousness, GCS E4 V5 M6, blood pressure 110/70 mmHg, pulse 82x/minute, RR 20x/minute, and temperature 36.7°C. On examination of the ophthalmological status, it was found that the visual acuity in the left eye was reduced, namely visual acuity OS 2/60. On the tonometry examination, it was found that the intraocular pressure in the left eye (IOP OS) was increased, namely 55.0 and palpebral edema was found, the conjunctiva was hyperemic, there was conjunctival injection and ciliary injection, the cornea was cloudy and edema, shallow anterior chamber and pupil mydriasis with a diameter of 5 mm.

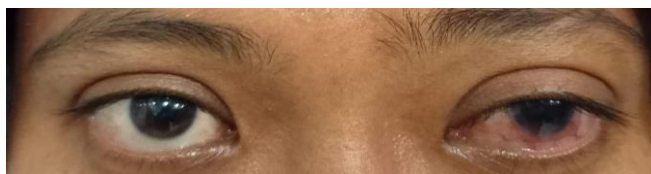

Figure 1 Clinical features of the patient

Based on the results of the anamnesis and physical examination of the patient above, Mrs. K was diagnosed with acute angle closure glaucoma oculus sinistra. The therapy plan in the above case consists of medical and surgical interventions. In medical interventions given:

- a) Timolol maleate 0.5% ED 2 dd gtt 1 OS
- b) Acetazolamide 250 mg 3x1
- c) KSR tab 1x1
- d) Pilocarpine HCL 2% ED 2 dd gtt 1 OS

In surgical intervention, OS trabeculectomy can be performed after the intraocular pressure is lowered.

The monitoring plan that will be carried out is that after medical intervention has been carried out for approximately 3 days, it is necessary to re-examine clinical complaints and examine ophthalmological status, including re-examination of intraocular pressure to relate to the consideration of surgical intervention that will be carried out.

Patients are given the following education :

- a) Providing education about the eye disease suffered, namely Glaucoma, the complications that will occur and the prognosis for vision.
- b) Provide education regarding the treatment that will be carried out in the form of how to use drops and possible surgical procedures that will be carried out.

The prognosis in this case is as follows:

- a) Ad Vitam : Dubia ad bonam
- b) Ad Functionam: Dubia ad bonam
- c) Ad Sanationam : Dubia ad bonam

This is because in acute angle closure, glaucoma, if treated immediately, will not cause permanent damage to the optic nerve of the eye, so permanent blindness may not occur.

Of the history and physical examination obtained, in the case of Mrs. K was diagnosed with Acute Angle Closure Glaucoma of Ocular Sinistra. Glaucoma is an eye disorder characterized by disturbances in the tissue and functional integrity of the eye with the characteristics of slowly progressive chronic optic neuropathy, which is characterized by the triad of typical optic nerve papillary atrophy, reduced or lost visual field width and increased intraocular pressure. 21 mmHg (Trihono et al., nd)

The most common etiopathogenesis of Glaucoma is obstruction of aqueous humor outflow due to pupillary block, closed anterior chamber angle, narrowing of the trabecular meshwork and increased episcleral venous pressure, thereby increasing intraocular pressure. Glaucoma is classified into 4, namely primary Glaucoma, secondary Glaucoma, congenital Glaucoma and absolute Glaucoma. Primary Glaucoma is divided into primary open-angle Glaucoma and primary closed-angle Glaucoma (Ministry of Health of the Republic of Indonesia, 2015).

In this case, Mrs. K experienced acute angle closure glaucoma. Acute angle closure glaucoma is included in the classification of primary angle closure glaucoma. Primary angle-closure Glaucoma (Figure 2) is an eye disorder that occurs due to a rapid increase in intraocular pressure as a sign of closure of the anterior chamber, obstructing the flow of aqueous humor (Prum et al., 2016).

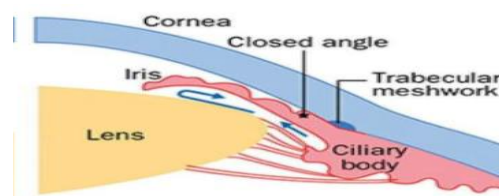


Figure 2 Primary Angle Closure Glaucoma

The mechanism of primary angle closure glaucoma is focused on the pupil, iris and ciliary body as well as the lens (Figure 3). The mechanism at the pupillary level is the pupillary block, in which there is an obstruction to the flow of aqueous humor between the anterior surface of the lens and the posterior surface of the iris. This causes the pressure in the posterior eye chamber to become high and pushes the iris posteriorly. This causes obstruction (Prum et al., 2016).

The mechanism at the level of the iris and ciliary body is the occurrence of anatomical abnormalities resulting in obstruction. The most common anatomical abnormality is the thickening and enlargement of the iris anterior to the ciliary body, which is located posteriorly, resulting in a narrow-angle. The mechanism at the lens level is caused by a thicker and more anteriorly positioned lens, resulting in a shallow anterior chamber and narrow angle (Prum et al., 2016).

Based on the explanation above, it can be concluded that primary angle closure glaucoma occurs when the angle is closed due to apposition of the peripheral iris caused by the underlying mechanism. This extension of apposition creates permanent adhesions between the peripheral iris and the trabecular meshwork, also called peripheral anterior synechiae (PAS) (Prum et al., 2016).

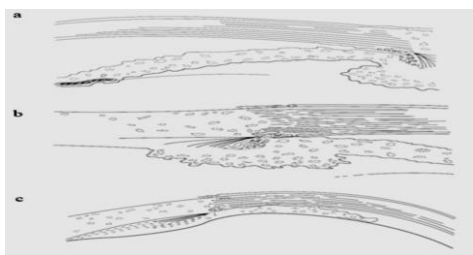


Image Caption 3:
a. Mechanism in the pupil
b. Mechanism in the iris and ciliary body
c. Mechanism in the lens

Figure 3 Mechanism of Primary Angle Closure Glaucoma

In general, primary angle closure glaucoma is classified into 4, namely as follows:

- a) Primary angle closure suspect (PACS) is found to have iridotrabecular contact $>180^\circ$. However, there is no evidence of damage to the trabecular tissue or optic nerve (Prum et al., 2016).
- b) Primary angle closure (PAC) was found to have iridotrabecular contact $>180^\circ$ with increased intraocular pressure^{but} without damage to the optic nerve (Prum et al., 2016).
- c) Primary angle closure glaucoma (PACG) is characterized by the presence of peripheral anterior synechiae (PAS) or increased intraocular pressure and signs of glaucomatous neuropathy (Sun et al., 2017).
- d) Acute angle closure crisis is characterized by symptoms of pain, either ocular or periocular, often accompanied by headache, nausea or vomiting with intraocular pressure > 21 mmHg and signs such as circumboreal congestion, corneal edema, dilated pupils, and shallow anterior chamber (Prum et al . al., 2016).

In this case, the same symptoms were also found in primary angle closure glaucoma, namely red eyes, epiphora, decreased vision, seeing rainbow colors around the light source (halo), sudden pain in the eye and its surroundings, nausea and vomiting. Physical examination revealed primary angle-closure Glaucoma:

- a) Decreased vision
- b) Palpebral edema
- c) Hyperemic and ciliary conjunctiva, chemosis
- d) Cloudy/gloomy cornea, edema
- e) Shallow anterior chamber, closed anterior chamber angle, aqueous flare (+)

- f) Iris atrophy
- g) Pupil mydriasis
- h) Increased intraocular pressure (50-100 mmHg)
- i) Fundoscopy: papillary excavation, edema, hyperemia
- j) Field of view: decreased

Apart from that, the signs and symptoms that appear in primary angle closure glaucoma also depend on the type classification. In PACS, patients generally do not show symptoms and are diagnosed incidentally. PAC is divided into three subtypes, namely acute, intermittent and chronic angle closure (Berkowitz et al., 2018). In conditions of acute angle closure, circular apposition of the iris to the trabecular meshwork causes a rapid and excessive increase in intraocular pressure, which does not resolve spontaneously, resulting in symptoms of headache, blurred vision, halos around lights, nausea, vomiting, increased intraocular pressure, dilated pupils. Slow and irregular corneal edema and flares (Prum et al., 2016). Other signs of acute primary angle closure glaucoma are conjunctival injection and dilated pupil (left), sectoral iris atrophy (middle) and glaucomflecken (right) (Figure 4) (Kalua, 2014).

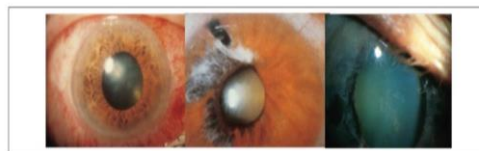

Figure 4 Signs of Acute Primary Angle Closure Glaucoma

In the case of Mrs. Apart from being based on the history and physical examination of ophthalmology and tonometry, other further examinations can be carried out, such as the van Herick method and gonioscopy. The van Herick method (Figure 5) is an examination method using a slit lamp in a dark room to see the anterior chamber compared to the thickness of the cornea. The van Herick method is used to determine the grading of the anterior chamber angle using a slit lamp with an angle of 60° directed close to the limbus, and there is a grading of 0 to 4 (Figure 6)

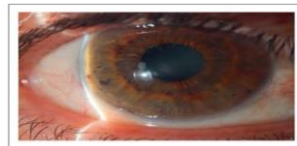

Figure 5 Van Herick Method Examination

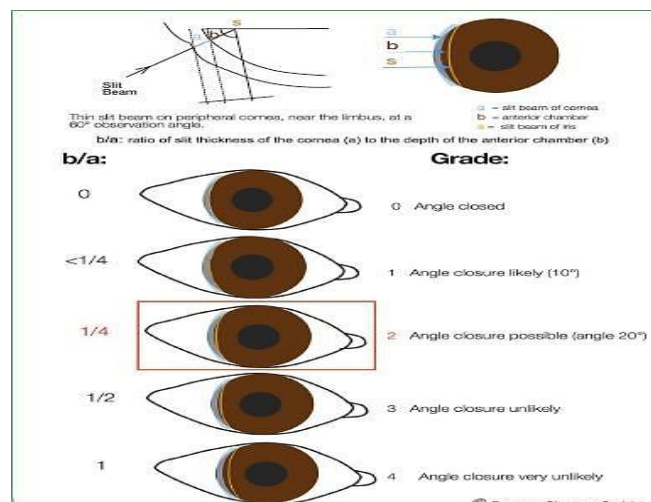


Figure 6 Van Herick Grading Method

Gonioscopy is used to determine the topography of the anterior chamber using specific gonio lenses. Dynamic gonioscopy or indentation gonioscopy can be performed to differentiate between appositional iris and PAS. The top image before indentation and the bottom image after indentation on the relative pupil block (Figure 7) (Prum et al., 2016).

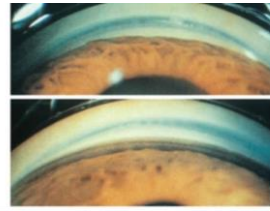


Figure 7 Gonioscopy examination

The gonioscopy assessment system uses the Shaffer assessment (Figure 8). In the Shaffer assessment, the results obtained are that result 0 is described when no meshwork trabeculae can be observed, result 1 is recorded when only Schwalbe lines and anterior meshwork trabeculae are visible, result 2 is recorded when the angle of the structure is visible only to the posterior meshwork trabecula, result 3 is first considered if all angular structures are visible down to the scleral spur and result 4 if all structures are visible down to the iris root and its attachment to the anterior ciliary body (Table 3)

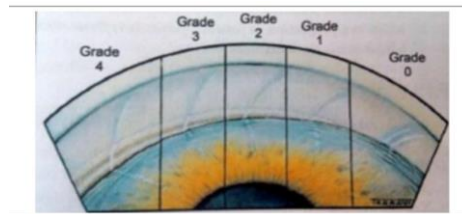


Figure 8 Shaffer's assessment

The diagnosis of Glaucoma can be carried out by supporting examinations such as examination of findings of Optic Nerve Head (ONH) damage and assessed subjectively through ophthalmoscopy, biomicroscopy, astrophotography or visual assessment of the visual field with automatic perimetry (Chauhan & Burgoyne, 2013). Apart from that, you can carry out scanning laser polarimetry (SLP), confocal scanning laser ophthalmoscopy (CSLO), optical coherence tomography (OCT) and ultrasound biomicroscopy (UBM) examinations.

The differential diagnosis of primary angle-closure Glaucoma is keratitis and acute iritis (Table 1).

Table 1 Differential Diagnosis of Primary Angle Closure Glaucoma

	Primary angle closure glaucoma	Keratitis	Acute Iritis
Cornea	Gloomy	Infiltrate	Clear
Front eye chamber	Shallow	Normal	Normal
Pupil	Mydriasis	Normal	Miosis
Intraocular pressure	Tall	Normal	Normal or low
Hyperemia	Conjunctiva and ciliary	Silver	Silver

There are two treatments for Glaucoma, namely medical intervention and surgical intervention. The medical interventions used are anti-glaucoma drugs such as alpha (α)-adrenergic agonists, beta (β)-adrenergic receptor antagonists, prostaglandin agonists, carbonic anhydrase inhibitors, epinephrine or a combination of two anti-glaucoma drugs, corticosteroids and myotic agents such as muscarinic acetylcholine agonists. Surgical interventions that can be performed are laser trabeculoplasty, trabeculectomy and laser iridotomy.

In this case, Timolol maleate 0.5% ED 2 dd gtt 1 OS therapy was given, a beta (β)-adrenergic receptor antagonist whose function is to reduce aqueous humor production. Apart from that, Acetazolamide 250 mg 3x1 therapy was also given, which is a class of carbonic anhydrase inhibitors

that functions to suppress the production of aqueous humor. Giving KSR tab 1x1 is used to prevent hypokalemia, which is a side effect of giving acetazolamide. In this case, Pilocarpine HCL 2% ED 2 dd gtt 1 OS was also given, which is a muscarinic acetylcholine agonist that acts as a miotic agent to contract the pupil. Using this drug can cause the iris to pull and move away from the trabecula so that the iridocorneal angle will open.

In this case, monitoring will be carried out for 3 days to see the effect of medical intervention in reducing intraocular pressure. After a decrease in intraocular pressure occurs as planned, surgical intervention will be carried out, which is the definitive therapy for acute primary angle closure glaucoma. Laser iridotomy is performed on primary angle closure glaucoma of the PAC and PACG types. In contrast, no therapy is performed on the PACS type because it is asymptomatic. Laser iridotomy is not performed in acute primary angle-closure Glaucoma due to corneal edema, so that a trabeculectomy can be performed.

Complications of Glaucoma include chronic corneal edema and permanent loss of central or peripheral vision. The prognosis for Glaucoma depends on the level of eye damage that has occurred. In this case, the prognosis tends to be good because acute angle closure glaucoma is an emergency condition in the eye. Intervention needs to be carried out as soon as possible, within 24-48 hours, so that in this case, if medical intervention can reduce intraocular pressure, then surgical intervention can be carried out immediately, which can prevent progressive eye nerve damage.

CONCLUSION

Glaucoma is an eye disorder characterized by slowly progressive chronic optic neuropathy, characterized by the triad of typical optic nerve papillary atrophy, reduced or lost visual field width and increased intraocular pressure > 21 mmHg. The most common causes of Glaucoma are obstructions in the outflow of aqueous humor due to pupillary block, closed anterior chamber angle, narrowing of the trabecular meshwork and increased episcleral venous pressure, thereby increasing intraocular pressure.

There are two treatments for Glaucoma, namely medical intervention and surgical intervention. The medical interventions used are anti-glaucoma drugs such as alpha (α)-adrenergic agonists, beta (β)-adrenergic receptor antagonists, prostaglandin agonists, carbonic anhydrase inhibitors, epinephrine or a combination of two anti-glaucoma drugs. Surgical interventions that can be performed are laser trabeculoplasty, trabeculectomy and laser iridotomy. Complications of Glaucoma include chronic corneal edema and loss of central or peripheral vision. The prognosis for Glaucoma depends on the level of eye damage that has occurred.

REFERENCES

- ayi Marini, I. N. A. (2018). Hubungan Tajam Penglihatan Dengan Kualitas Hidup Klien Glaukoma Di Poli Glaukoma Di Pusat Mata Nasional Rumah Sakit Mata Cicendo Bandung.
- Berkowitz, S. J., Wei, J. L., & Halabi, S. (2018). Migrating to the modern PACS: challenges and opportunities. *RadioGraphics*, 38(6), 1761–1772.
- Brown, R. H., Zhong, L., & Lynch, M. G. (2014). Lens-based glaucoma surgery: using cataract surgery to reduce intraocular pressure. *Journal of Cataract & Refractive Surgery*, 40(8), 1255–1262.
- Bustami, A., Karyus, A., & Anita, A. (2022). Penatalaksanaan Holistik Pasien Hipertensi Derajat II Tidak Terkontrol dan Dispepsia Melalui Pendekatan Keluarga. *Jurnal Ilmu Kesehatan Indonesia (JIKSI)*, 3(1).
- Chauhan, B. C., & Burgoyne, C. F. (2013). From clinical examination of the optic disc to clinical assessment of the optic nerve head: a paradigm change. *American Journal of Ophthalmology*, 156(2), 218–227.
- EGS. (2017). Terminology Guidelines. In European Glaucoma Society Foundation (Issue March).

- Fatmawaty, D. (2019). Asuhan Keperawatan Pada Pasien Diabetes Mellitus Dengan Masalah Keperawatan Kerusakan Integritas Kulit Di RSUD Dr Hardjono Ponorogo. Universitas Muhammadiyah Ponorogo.
- Fitriana, D., & Sureskiarti, E. (2018). Analisis Praktik Klinik Keperawatan pada Pasien dengan Chronic Kidney Disease dengan Intervensi Efektivitas Afirmasi Positif dan Stabilisasi Dzikir Vibrasi sebagai Media Terapi Psikologis untuk Mengatasi Kecemasan pada Pasien Hemodialisa di Ruang Hemodial.
- Ice Rerung, S., Said, S., Ayu Erika, K., Keperawatan, M., Keperawatan, F., Hasanuddin, U., Selatan, S., Keperawatan Medikal Bedah, D., & Sains dan Kesehatan, J. (2021). Jenis dan Efek Complementary Therapy dalam Menurunkan Tekanan Intra Okular (TIO) pada Pasien Glaukoma: A Systematic Review Types and Effects of Complementary Therapy in Reducing Intra-Ocular Pressure (IOP) in Glaucoma Patients: A Systematic Review. *J. Sains Kes.*, 3(3), 544.
- Juliawan, K. D., & Mayasari, D. (2023). Penatalaksanaan Holistik Penyakit Diabetes Melitus Tipe 2 Tidak Terkontrol Dan Hipertensi Pada Wanita Dewasa Belum Menikah Melalui Pendekatan Kedokteran Keluarga. *Medical Profession Journal of Lampung*, 13(3), 387–397.
- Kalua, K. (2014). Hubungan antara Glaukoma dengan Diabetes Melitus dan Hipertensi. Kementerian Kesehatan RI. (2015). InfoDATIN Pusat Data dan Informasi Kementerian Kesehatan RI: Situasi dan Analisis GLAUKOMA. In Pusat Data dan Informasi (pp. 1–6).
- Prum, B. E., Herndon, L. W., Moroi, S. E., Mansberger, S. L., Stein, J. D., Lim, M. C., Rosenberg, L. F., Gedde, S. J., & Williams, R. D. (2016). Primary Angle Closure. *Ophthalmology*, 123(1), P1–P40. <https://doi.org/10.1016/j.ophtha.2015.10.049>
- Ridiansyah, A. N. A., Fadila, A. N., Piningit, B. F. A., Afifah, D., & Nugroho, R. I. (2022). EVIDENCE BASED PRACTICE Perbedaan Tingkat Nyeri Pada Pasien Vertigo Sebelum dan Setelah dilakukan Terapi Akupuntur dan Bekam Di Klinik Arga Holistik Care Glenmore Banyuwangi.
- Sun, X., Dai, Y., Chen, Y., Yu, D.-Y., Cringle, S. J., Chen, J., Kong, X., Wang, X., & Jiang, C. (2017). Primary angle closure glaucoma: what we know and what we don't know. *Progress in Retinal and Eye Research*, 57, 26–45.
- Trihono, P. P., Djer, M. M., & Citraresmi, E. (n.d.). *Practical Management in Pediatrics*.
- Vijaya, L., Manish, P., Ronnie, G., & Shantha, B. (2011). Management of complications in glaucoma surgery. *Indian Journal of Ophthalmology*, 59(SUPPL. 1). <https://doi.org/10.4103/0301-4738.73689>
- Winangsih, R., & Sariyani, M. D. (2021). Gambaran Pengetahuan HIV/AIDS Pada Ibu Rumah Tangga Di Desa Sambirenteng Kecamatan Tejakula Kabupaten Buleleng Tahun 2020. *Jurnal Medika Usada*, 4(1), 34–39.